

# Stress Echo & Valvular Heart Disease:


*Who, Why and ...Wait*

Shaheeda Ahmed, MD, FRCPC, FACC  
Schulich Heart Program, SHSC, University of Toronto

Canadian Society of Echo, April 24, 2015, Toronto, ON.




# Objectives



- *Who*
  - Recognize which patients with native left sided valvular heart disease may benefit from stress echocardiography (SE)
- *Why*
  - Understand the rationale behind SE in these patients
- *And Wait...*
  - Recognize limitations and promising new applications

# Stress Echo Methods




## GUIDELINES AND STANDARDS

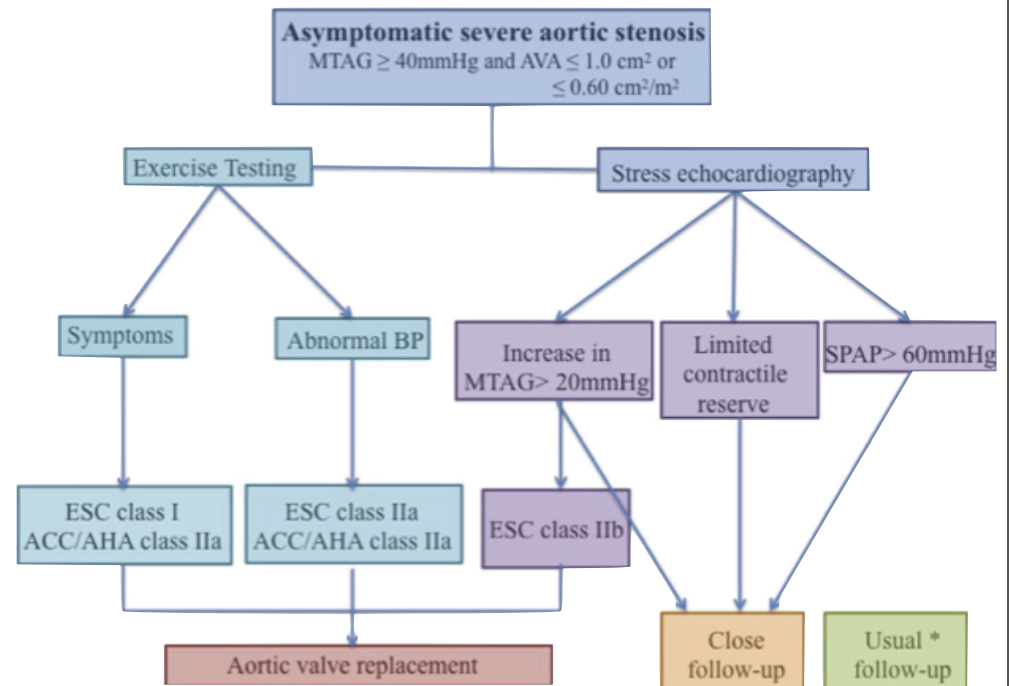
### American Society of Echocardiography Recommendations for Performance, Interpretation, and Application of Stress Echocardiography

Patricia A. Pellikka, MD, Sherif F. Nagueh, MD, Abdou A. Elhendy, MD, PhD,  
Cathryn A. Kuehl, RDCS, and Stephen G. Sawada, MD, *Rochester, Minnesota; Houston,  
Texas; Marshfield, Wisconsin; and Indianapolis, Indiana*


# Key Points



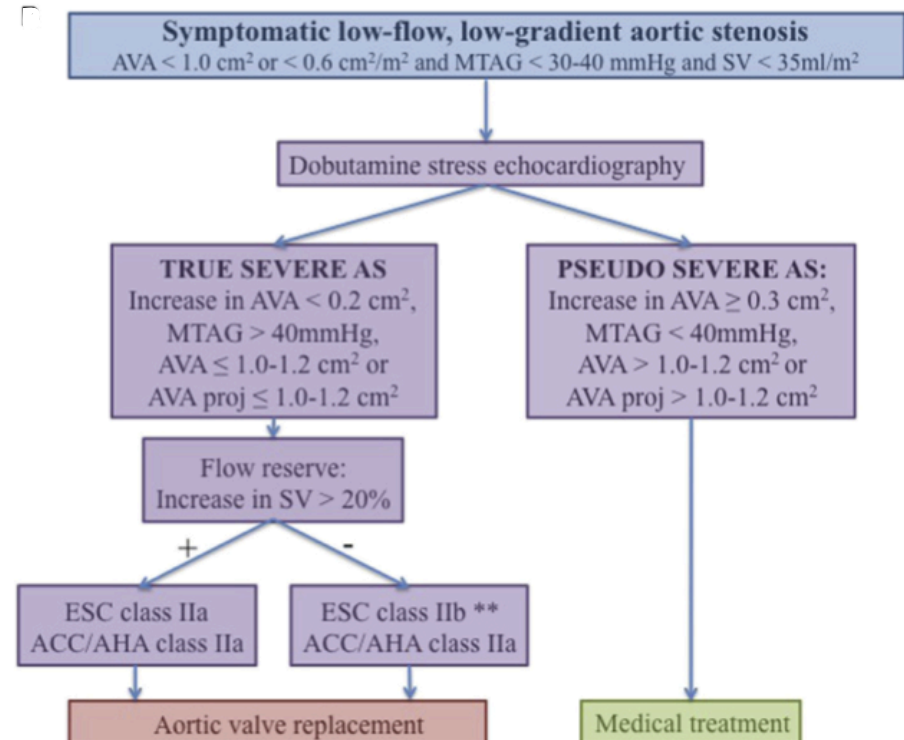
- Regular stress testing reasonable in asymptomatic severe AS patients
- Abnormal test merits AVR (Class I, ACC, ESC)
- Exercise echo
  - Improves risk stratification (?early surgery)
  - Consider AVR for rise in mean gradient  $>20\text{mmHg}$  ?(Class IIb, ESC)




# Key Points



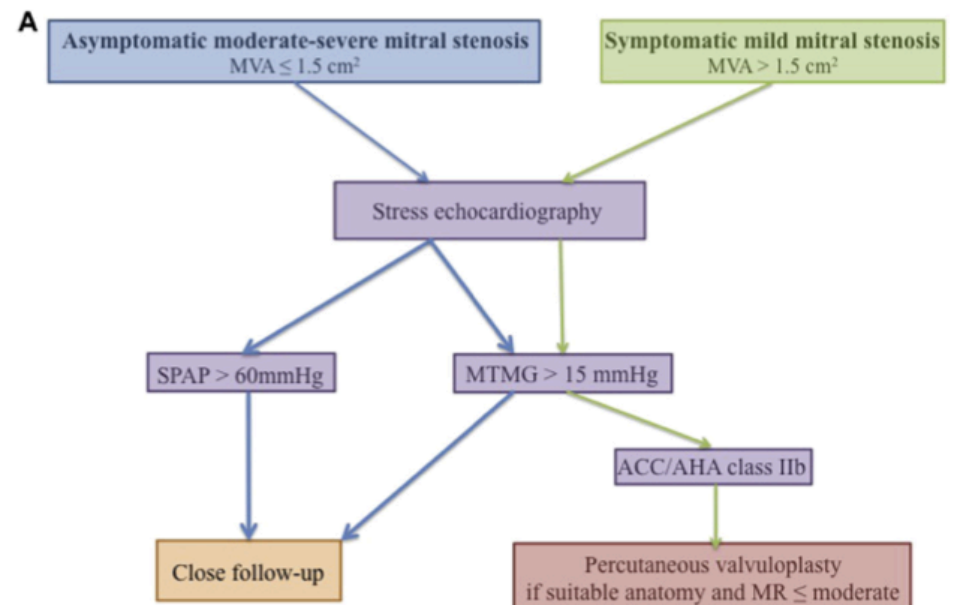
- Dobutamine Stress and Severe AS
  - Low dose
  - Presence of flow reserve helpful
  - No flow reserve  $\neq$  No LV recovery
  - Consider Projected AVA  $\leq 1.0\text{cm}^2$  or  $\leq 0.55\text{cm}^2$
  - ? CT for AV calcium quantification




# Key Points



- Useful if symptoms with  $MVA > 1.5 \text{ cm}^2$  at rest, also if asymptomatic  $< 1.5 \text{ cm}^2$
- Exercise stress echo preferable
- Change in  $MTMG > 15 \text{ mmHg}$  (exercise) or  $18 \text{ mmHg}$  (dobutamine) predicts events
- Early rise and large relative rise in  $RVSP$ ?



# Key Points



## Primary MR

- Negative prognostic factors with exercise:
  - Reduced functional capacity
  - ERO increases by more than **10mm<sup>2</sup>** or RV by **>15ml**
  - RVSP **>54mmHg**
  - RV dysfunction (**TAPSE <19mm**)
  - Abnormal LV response (no change in **EF by 4%** or GLS change **<2%**)
- Interpret RVSP cautiously -? **Surgery if RVSP ?60mmHg** (ESC 2012, not ACC)

## Secondary MR

- More **complex**, may be helpful:
  - Etiology
  - Symptoms, severity, RVSP
  - Chronic HF: **ERO change  $\geq$  13mm<sup>2</sup>** worse

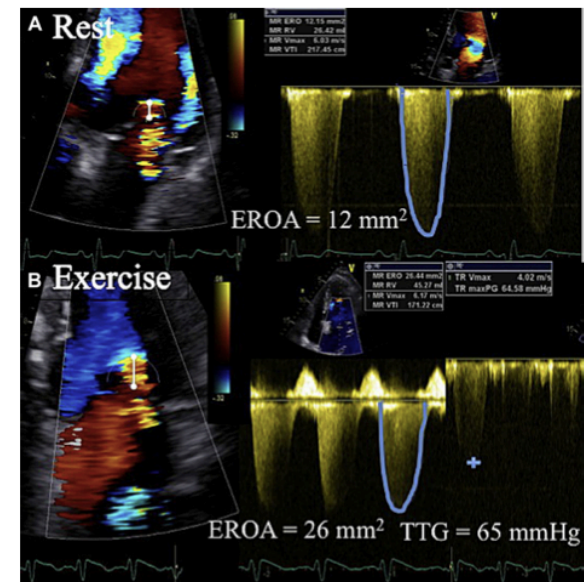



Figure from Henri C CJC; 2014 (30): 1012-1026


# Aortic Regurgitation



- Not recommended for clinical routine use by ACC or ESC valve guidelines
  - Few studies with AR and stress echocardiography
  - Focus on LV parameters
    - Dobutamine stress echo for viability
    - Subclinical LV dysfunction using LVEF or strain
    - Prognosis worse (LV dysfunction, earlier surgery) if LVEF does not change by 5% or LVESD does not decrease



# Key References



- Pellika P. et al. JASE 2007; 20: 1021-1041
- Nishimura R, JACC 2014; 63(22):2438-2488;
- Bax JJ. EHJ 2012; (33): 2451-2496
- Henri C CJC; 2014 (30): 1012-1026
- Lancellotti P et al. Circ Cardiovasc Imaging.2013 ;6:840-849
- Clavel MA et al. J Am College Img: 2013 ; 6:175
- Kusunose K et al. Circ Cardiovasc Imaging.2014 ;7:352-362